

# A case of pure neuritic form of Hansen's disease with associated severe iron deficiency anemia

Ravishankar, SN.<sup>1</sup>, Madhuvan, HS.<sup>2</sup>, Dr. Gale Kathleen<sup>3</sup>, Sunil, GK.

**1** Associate Professor (Dept of Medicine). Akash Institute of Medical Sciences and Research Centre, Devanahally.

**2** Assistant Professor (Dept of Medicine). Akash Institute of Medical Sciences and Research Centre, Devanahally.

**3** Assistant Professor (Dept of Dermatology). Akash Institute of Medical Sciences and Research Centre, Devanahally.

**4** Assistant Professor (Dept of Pathology). Akash Institute of Medical Sciences and Research Centre, Devanahally.

Corresponding author:

✉ [dr.ravishankar.sn@gmail.com](mailto:dr.ravishankar.sn@gmail.com)



This article is available from:  
[www.archivesofmedicine.com](http://www.archivesofmedicine.com)

## Abstract

Leprosy is one of the most common treatable dermato-neurologic disease affecting skin and peripheral nerves. Though the prevalence of the disease is decreasing, still it is a major public health problem in India. Pure neuritic leprosy constitutes 4 – 10% of all leprosy cases. The diagnosis of such case is difficult because of lack of skin lesions. Therefore it requires high degree of suspicion and thorough investigations. Association of anaemia with leprosy is commonly due to nutritional and impaired utilization of iron and studies have quoted impaired iron metabolism and defective megaloblastic erythropoiesis. Our case is a pure neuritic form of leprosy with unusual finding of ulnar cyst at right elbow joint and also had severe degree of Iron Deficiency Anemia. It was a diagnostic challenge requiring high degree of clinical suspicion and thorough investigations.

**Key words:** neuritic leprosy, ulnar nerve cyst, severe Iron Deficiency Anemia, diagnosis dilemma.

## Introduction

Leprosy (Hansen's disease) is one of the common treatable dermato-neurological disease affecting the skin and peripheral nerves. The prevalence of disease is decreasing but still represents one of the major public health problems mainly in India and Brazil [1-3]. Leprosy with skin changes and peripheral nerve involvement can be diagnosed clinically. Where as pure neuritic type poses difficulty in making diagnosis due to the absence of typical dermatological features.

We report a case of unusual presentation of leprosy with multiple peripheral nerve thickening which are tender and the right ulnar nerve forming a cystic lesion at right elbow joint and having severe iron deficiency anaemia.

Iron deficiency anaemia in leprosy is possibly due to the underlying disturbances in iron metabolism and in erythropoiesis and other cytomorphological changes in bone marrow.

Iron deficiency anaemia in pauci bacillary leprosy is usually mild to moderate, but in Multibacillary leprosy it is severe. It is also shown that iron metabolism and erythropoiesis were affected to a lesser degree in patients receiving specific anti-leprosy treatment, irrespective of type of disease and duration of treatment positivity of AFB.

Hence in countries like India, polyneuritic type of leprosy with difficulty in making diagnosis associated with anaemia requires high degree of suspicion and thorough investigations to manage the patient.

## Case Report

A 60 yrs old male patient presented with h/o weakness in all four limbs more in right upper and right lower limb. Pain right elbow joint since 6 months. Patient was non diabetic, non hypertensive, nonsmoker and non alcoholic. On General examination- Patient had severe conjunctival/skin pallor with platynychia of nails, pale & bald tongue.

- Right hand-shows claw deformity.
- Wasting of hand/forearm muscles more in right hand.
- Right ulnar nerve thickening- with cystic changes at elbow joint.
- No skin changes – no trophic changes.

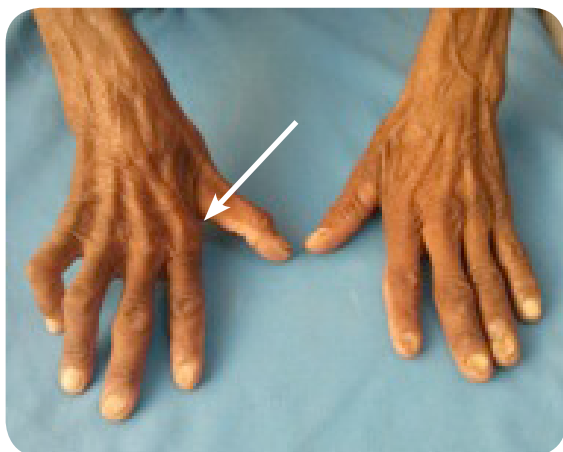

Fig 1. Showing muscle wasting and nail changes of anemia.

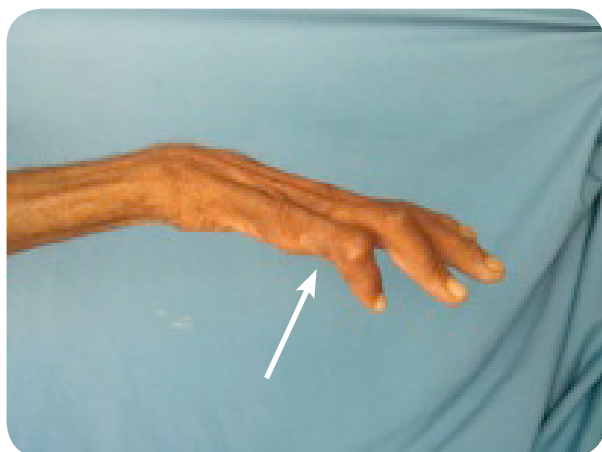


Fig 2. Showing ulnar claw hand.

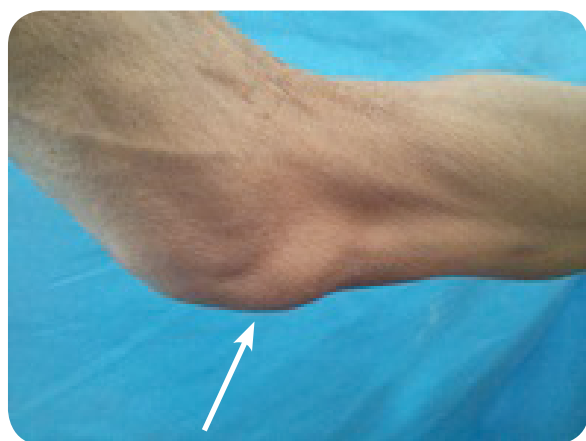

Fig 3. Showing right ulnar nerve thickening with cyst formation.

### Systemic examination

**CNS:** patient conscious, oriented.

Sensory disturbances, in the form of distal stocking/glove distribution on Right UL and both LL with thermal and pinpoint anesthesia and preservation of proprioception. Both planters are flexors.

Other systems: normal.

Lab investigations revealed- microcytic hypochromic anaemia of Hb 5 gm%.

Blood sugar, RFT, LFT were normal, VDRL, HIV, HBSAg were negative, CXR- normal, nerve conduction velocity study was abnormal suggestive of mixed (axonal demyelination) sensory motor neuropathy.

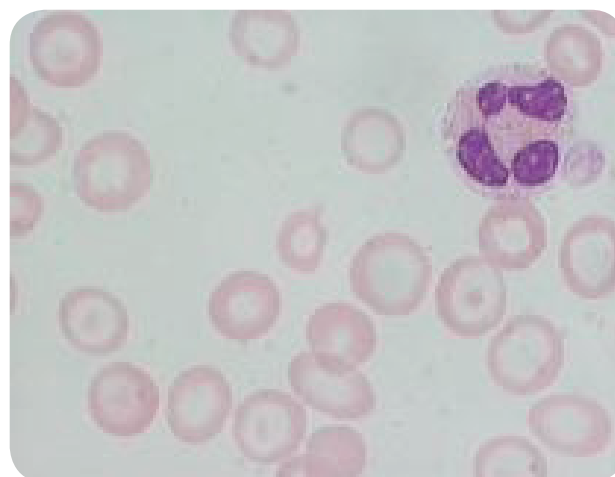


Fig 4. Showing microcytic hypochromic blood picture.

### Discussion

Hansen's disease (leprosy), the prevalence of the disease though is decreasing, the diagnosis and management has become a challenge in the medical field especially the pure neuritic type of the disease without dermatological features. Also the association of anaemia with the disease with multiple causative possibilities. Many studies have shown both Iron Deficiency Anemia/Macrocytopenia both in Paucibacillary and Multibacillary of variety of disease. In our case the anemia (Iron Deficiency Anemia) association, also the ulnar nerve enlargement with cyst formation is a distinct variation. We report this case because of its unusual presentation of polyneuritic type and neuronal cyst formation and association with severe iron deficiency anaemia. Neural leprosy is difficult to diagnose in the absence of skin lesions but the ty-

pical neural thickening and tenderness associated with gross muscle wasting. Also causing claw hand deformity in Rt hand. This form of leprosy is still active in India and its diagnosis is usually missed. There is need to pay more attention to this form of leprosy to diagnose and treat patients earlier and to prevent sequale.

In conclusion unusual presentation of leprosy should be clinically suggested as pure neuritic leprosy and thoroughly investigated for better management.

## References

1. Andrade, V., Militao de Albuquerque, MD., Chagastelles Sabroza, P. The importance of operational factors for the interpretation of indicators in the Hansen's disease endemic in Brazil. *Acta Leprol.* 1997; 10: 131-139.
2. - Talwar, S., Jha, PK., Tiwari, VD. Neuritic leprosy: Epidemiology and therapeutic responsiveness. *Lepr Rev.* 1992; 63: 263-268.
3. Noorden, SK. Elimination of leprosy as a public health problem: progress and prospects. *Bull WHO* 1995; 73: 1-6.
4. Girdhar, BK. Neuritic leprosy. *Indian J Lepr.* 1996; 68: 35-42.
5. Jennekens, FGI., Van Brakel, WH. Neuropathy in leprosy. Latov, N., Wokke, K. (Eds.). *Immunological and infectious disease of peripheral nerves.* Cambridge: Cambridge Univ. Press, 1998, pp. 319-339.
6. Vijaikumar, M., D'souza, M., Kumar, S., Badhe, B. Fine needle aspiration cytology (FNAC) of nerves in leprosy. *Lepr Rev.* 2001; 72: 171-8.

### Comment on this article:



**Medicalia.org**

Where Doctors exchange clinical experiences, review their cases and share clinical knowledge. You can also access lots of medical publications for free. **Join Now!**

<http://medicalia.org/>

### Publish with iMedPub

<http://www.imedpub.com>

- ✓ Archives of Medicine encompasses all aspects of medical science and clinical practice and cooperates closely with
- ✓ Archivos de Medicina, a Spanish-language open access journal.

#### Submit your manuscript here:

**Archives of Medicine**

<http://www.archivesofmedicine.com>

**Archivos de Medicina**

<http://www.archivosdemedicina.com>