

A case of bronchiectasis with infertility? Primary ciliary Dyskinesia

Dr. Madhuvan, HS.¹,
Dr. Ravishankar, SN.²,
Dr. Kailash, MS.¹,
Dr. Thimma Reddy, SR¹

Department of General Medicine,
Akash Institute of Medical Sciences
and Research Center, Devanahalli,
Bangalore.

1 Assistant Professor
2 Associate Professor

Corresponding author:

 drmadhuvanhs@gmail.com

Abstract

Primary ciliary dyskinesia (PCD) is a genetic disorder characterised by chronic rhinosinusitis, bronchiectasis, dextrocardia in approximately 50% of cases, and male infertility. PCD is a rare syndrome with an estimated incidence of 1: 20,000 to 30,000. Here by we by report a case of bronchiectasis associated with infertility in a middle aged man secondary to primary ciliary dyskinesia.

Key words: primary ciliary dyskinesia, bronchiectasis, infertility.

Introduction

Bronchiectasis refers to an irreversible airway dilatation that involves the lung in either a focal or a diffuse manner and that classically has been categorized as cylindrical or tubular (the most common form), varicose, or cystic.

Primary Ciliary Dyskinesia (PCD) (Immotile ciliary syndrome), is a rare, ciliopathic, autosomal recessive genetic disorder that causes a defect in the action of the cilia lining the respiratory tract (lower and upper, sinuses, Eustachian tube, middle ear and fallopian tube, and also of the flagella of sperm in males).

It has been well established that there are associations between bronchiectasis or chronic bronchitis and male infertility. Because of this affected individual develops chronic recurrent sino-pulmonary infection, impaired tracheobronchial clearance, situs inversus in about 50%

of cases, and living but immotile spermatozoa of normal morphology. Kartagener syndrome and Young's syndrome are included as a subgroup or part of this syndrome.

We here by report a case of bronchiectasis associated with infertility.

Case report

Mr. M, 32/M presented to OPD of Akash Hospital, Devanahalli, with h/o cough with copious foul smelling sputum production since 6 months. H/o fever since a week. No h/o hemoptysis.

He had similar complaints in the childhood and was admitted for the same. There was no h/o TB in the past.

He is a nonsmoker and had never consumed alcohol. There was no history suggestive of otitis media, gastrointestinal disease, cardiac failure, or genital infection.

There was no family history of similar complaints. He is married for 10 years and has no issues, however he has normal libido. Infertility work up of wife was found to be normal.

On Examination

Pt moderately built and nourished, digital clubbing +, cyanosis +, vitals were stable.

Respiratory system examination revealed bilateral extensive coarse crepitations (R>L).

Other systems normal.

Secondary sexual features including testicular size are normal.

His investigations reveal normal blood counts, blood biochemistry, urine analysis, etc. Serological tests for HIV and HBsAg were nonreactive. Sputum smear microscopy was negative for acid-fast bacilli. Sputum culture was grew *Pseudomonas aeruginosa* species. Pulmonary function tests revealed mild obstructive type of ventilatory defect

Semen analysis revealed a volume of 3 mL with normal sperm count (45 million) with 70% non motility (**asthenospermia**).

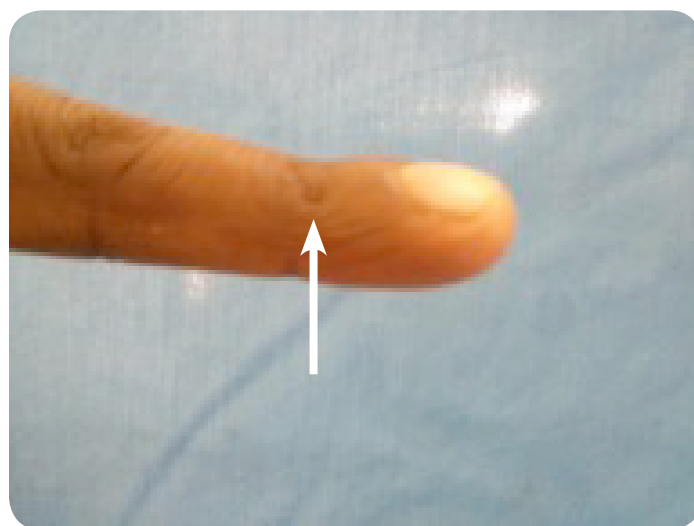

Fig. 1. Showing digital clubbing.

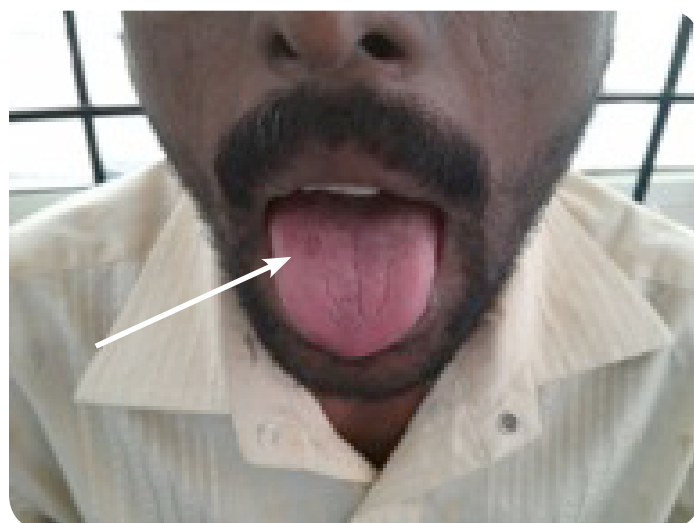


Fig. 2. Shows cyanosis.

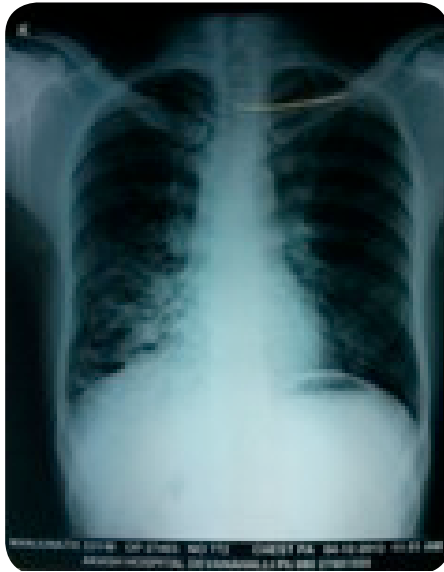

Fig. 3. CXR showing cystic lucencies in right lower zone.

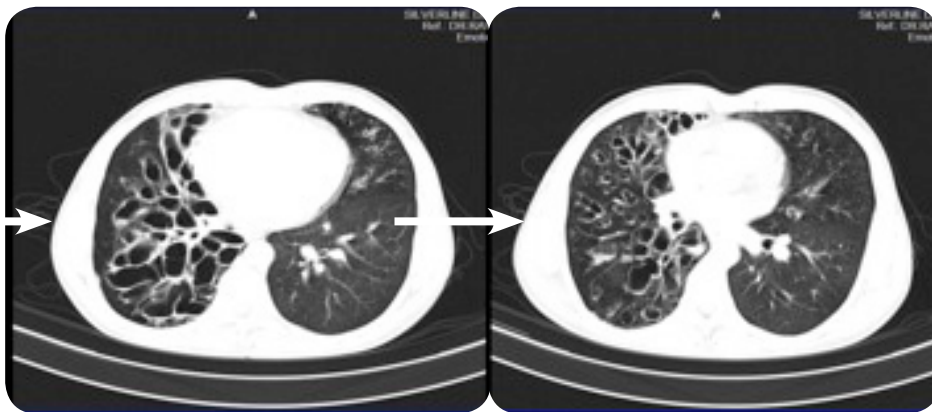


Fig. 4. Shows cystic bronchiectatic changes with air fluid levels.

Chest X Ray shows multiple thin walled cystic lucencies in Right lower zone with few of them showing air fluid changes.

X-ray paranasalsinu was normal.

CT scan thorax showed classical cystic bronchiectatic changes with few showing air fluid levels predominantly involving the right middle and lower lobes.

Pt treated with appropriate antibiotics and other supportive measures with good recovery from the pulmonary infection.

After detailed evaluation pt was advised IVF.

Discussion

Bronchiectasis is a pathological description of the lungs characterised by inflamed and dilated thick-walled bronchi. Disorders of ciliary structure or func-

tion result in impaired clearance, leading to chronic rhino-sinusitis, otitis media, nasal polyposis, and ultimately bronchiectasis. This is also associated with reduction in sperm motility, resulting in infertility.

Immotilecilia syndrome is an autosomal recessive defect characterised by immobility or poor motility of cilia in airway and sperms. Kartagener's syndrome is a subgroup of immotile cilia syndrome associated with situsinverus, chronic sinusitis and bronchiectasis.

Young's syndrome however, is characterised by a congenital epididymis obstruction with bronchiectasis and differs from the immotilecilia syndrome by the absence of ultrastructuralcilial disorders and from cystic fibrosis by the presence of normal sweat and pancreatic functions.

The typical clinical picture of PCD is a chronic productive cough which can usually be traced back to early childhood or infancy, chronic rhinitis often with nasal polyposis, chronic or recurrent maxillary sinusitis, and frequent ear infections in childhood. Bronchiectasis is not present at birth, but may develop early, sometimes even in childhood. The most common respiratory pathogens are *Haemophilus influenzae* and *Streptococcus pneumoniae*. In our case *pseudomonas aeruginosa* was grown.

Most males are sterile, but many females have a lowered fertility. About 50% of patients have situs-inversusviscerum.

The aim of reporting the case is the proved association between bronchiectasis and infertility and the possibility of PCD in our case.

Studies have shown the incidence of such association is very minimal though it is documented. With proper treatment for clearing the infectio , an with assisted IVF the chances of conceiving may improve.

References

1. Eliason, R., Mossberg, B., Camner, P., Afzelius, BA. The immotile cilia syndrome: A congenital ciliary abnormality as an etiologic factor in chronic airway infection and male sterility. *N Engl. J Med.* 1977; 297: 1-6
2. Sangeeta, A.,aKarande, S.,aLimaye, C., Dsouza, R. Young Syndrome. *Bombay Hospital Journa .* 2011; 53 3),.672-673.
3. Bandyopadhyay, D., Bose, S., Majumder, S., Bandyopadhyay, S. Young's Syndrom : An uncommon cause of bronchiectasis.:*Journal, Indian Academy of Clinical Medicine* 2004; 5 (4). 351-3.
4. Seaton, D. Bronchiectasis. In: Seaton, A., Seaton, D., Lietch, AG, (ers.). *Crofton and Douglas's respiratory diseases.* Oxford: Blackwell Science; 2004. pp. 794-828.
5. Longo, AS., Kasper, DL. et al. Bronchiectasis. *Harrison's principles of internal medicine.* 18th edition. chapter 258.
6. Pamela, B., Davis, Van S., Hubbard, A., Garvin, J. Bronchiectasis and oligospermia: Two families. *Thorax* 1985; 40: 376-379.
7. Neil, C., Munro. et al. Fertility in men with primary ciliary dyskinesia presenting with respiratory infection.:*Thorax* 1994; 49: 684-687.

Comment on this article:



<http://medicalia.org/>

Where Doctors exchange clinical experiences, review their cases and share clinical knowledge. You can also access lots of medical publications for free. **Join Now!**

Publish with iMedPub

<http://www.imedpub.com>

Archives of Medicine encompasses all aspects of medical science and clinical practice and cooperates closely with Archivos de Medicina, a Spanish-language open access journal.

Submit your manuscript here:

Archives of Medicine
<http://www.archivesofmedicine.com>

Archivos de Medicina
<http://www.archivosdemedicina.com>